

Canine Cancer Panel Report



VDI Lab Services
 4685 Runway St. Ste K Simi Valley, CA 93063
 ph: 805-577-6742 fax: 805-426-8115


PATIENT NAME: Maggie Kostyzak
SPECIMEN ID: 452251
SPECIES: Canine
GENDER: Female Spayed
AGE: 13.0
WEIGHT: 22.6 lb
BREED: Scottish Terrier

MRN: 1044641
DRAW DATE: 7-Mar-22
RECEIVED DATE: 14-Mar-22
REPORT DATE: 14-Mar-22
SAMPLE TYPE: Dried Serum - 2
PATIENT STAGE: Remission
TREATMENT: unknown

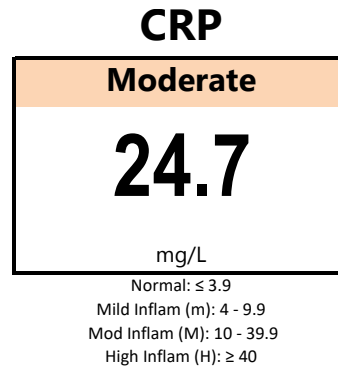
VETERINARIAN:
FACILITY:
PH:
FAX:

Relevant Context (provided on TRF)

<input type="checkbox"/> Corticosteroids	<input type="checkbox"/> Antibiotics	<input type="checkbox"/> Suspected Mass	<input type="checkbox"/> Hypercalcemia
<input type="checkbox"/> NSAIDs	<input type="checkbox"/> Anemia	<input type="checkbox"/> Enlarged Node	<input type="checkbox"/> B12 Deficiency
<input type="checkbox"/> Chemotherapy	<input type="checkbox"/> GI Signs	<input type="checkbox"/> Fever	<input type="checkbox"/> Known Disease




Significant Change



Trending



CAR: 6.7



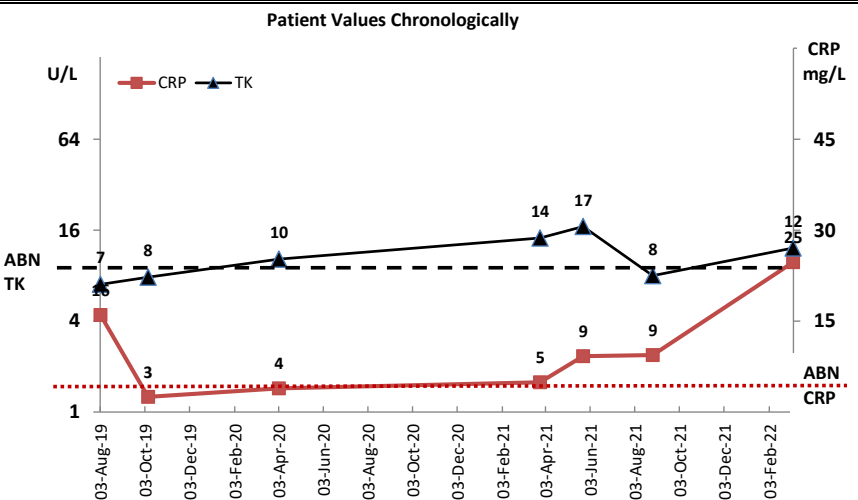
Interpretative Comment

Patient values for TK1 are above the critical threshold and CRP is severely elevated. TK1 has significantly increased from prior testing with CRP steadily increasing as well. Recommend immediate patient evaluation for disease recurrence. Patient CRP/Albumin Ratio (CAR) is MODERATE suggestive of elevated risk of serious disease and the patient may be struggling to manage the heightened level of inflammation. Evaluate patient further.

Gaps in charting occur when there is more than 6 months between testing intervals

3.7

Spec ID	Date	TK Value	CRP Value	Neoplasia Index*
404156	03-Aug-19	7.0	16.0	7.6
414997	07-Oct-19	7.8	2.5	3.5
422408	03-Apr-20	10.3	3.9	5.3
436104	26-Mar-21	14.2	4.9	8.2
434865	24-May-21	16.9	9.2	8.2
442784	27-Aug-21	8.0	9.4	5.8
452251	07-Mar-22	12.2	24.7	9.9



*Neoplasia Index is primarily used for initial diagnosis, and is typically not associated with patients undergoing therapy for known cancer.

Additional Reviewer Comments

Code 3453.1

All comments are general in nature and in absence of detailed knowledge of patient status or treatment.
 For case-specific consultations, please contact VDI.

Reviewer: RR