



PATIENT NAME: Milo Aoun
SPECIMEN ID: 466530
SPECIES: Feline
GENDER: Male Neutered
AGE: 5.5
WEIGHT: 16.6 lb
BREED: DSH

MRN: 1086020
DRAW DATE: 17-Sep-22
RECEIVED DATE: 23-Sep-22
REPORT DATE: 23-Sep-22
SAMPLE TYPE: Dried Serum - 2
PATIENT STAGE:
TREATMENT: unknown

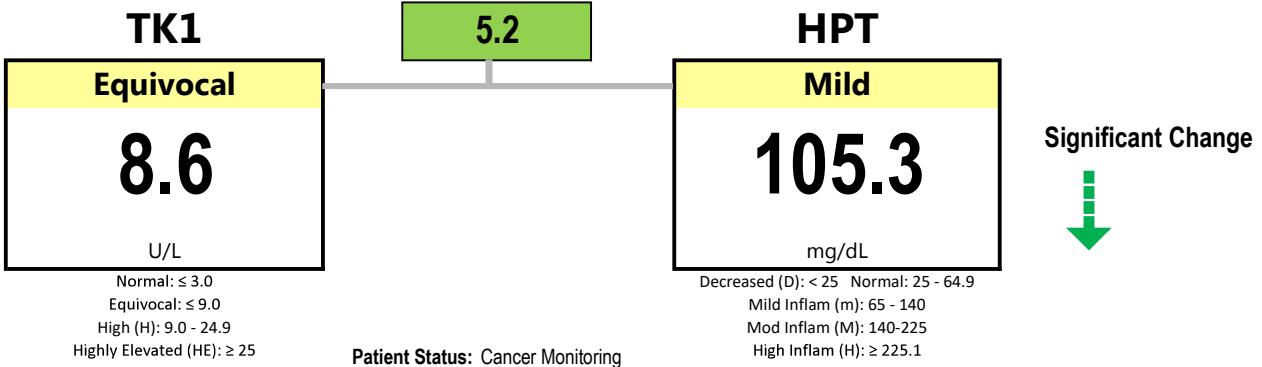
VETERINARIAN:
FACILITY:
PH:
FAX:

Relevant Context (provided on TRF)

Corticosteroids Antibiotics Suspected Mass Hypercalcemia
 NSAIDs Anemia Enlarged Node B12 Deficiency
 Chemotherapy GI Signs Fever Known Disease

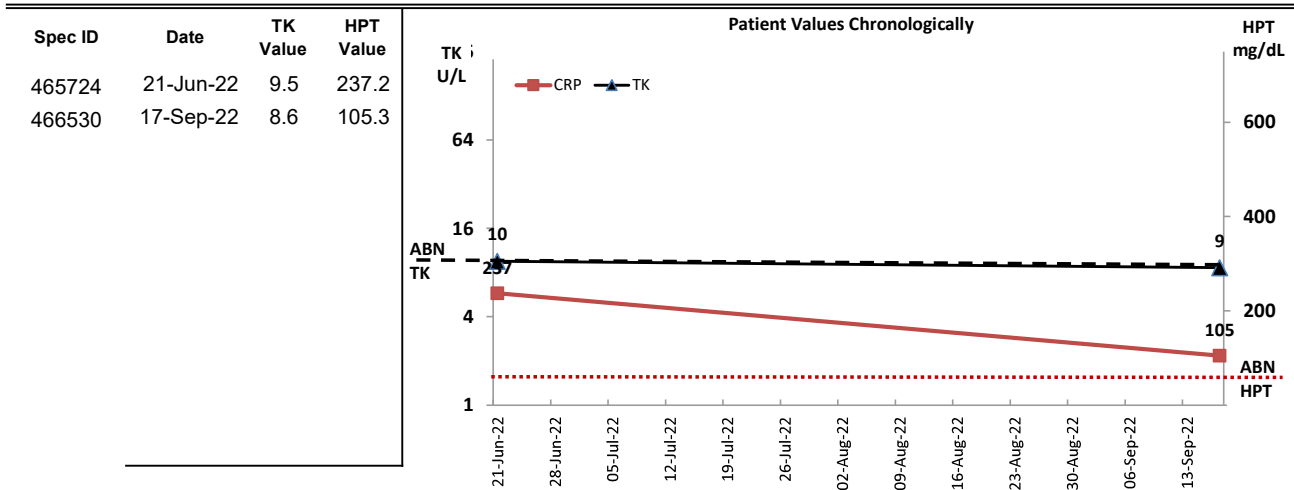
Neoplasia Index

Positive: 5.4 - 10



Intpretative Comment

Patient values for TK1 and HPT are mildly elevated. TK1 remains stable with significant improvement in the inflammatory state of the patient. If patient is under treatment, therapy can be considered effective. If the patient is on corticosteroids, other anti-inflammatory medication, or has uncontrolled Cushings, it can suppress HPT.



Additional Reviewer Comments - need consult? email consult@vdlab.com

Code 2242.1

All comments are general in nature and in absence of detailed knowledge of patient status or treatment.
For case-specific consultations, please contact VDI.

Reviewer: RR