



**PATIENT NAME:** Pacha Rodriguez  
**SPECIMEN ID:** 457172  
SPECIES: Feline  
GENDER: Male Neutered  
AGE: 9.0  
WEIGHT: 10.12 lb  
BREED: DLH

**MRN:** 1077996  
DRAW DATE: 23-Sep-22  
RECEIVED DATE: 26-Sep-22  
REPORT DATE: 27-Sep-22  
SAMPLE TYPE: Dried Serum - 2  
PATIENT STAGE:  
TREATMENT: unknown

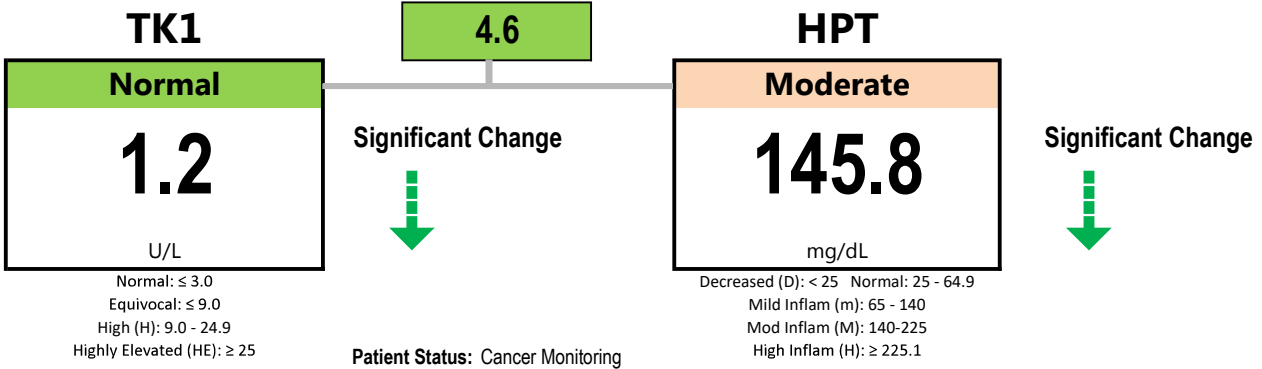
**VETERINARIAN:**  
FACILITY:  
PH:  
FAX:

Relevant Context (provided on TRF)

Corticosteroids     Antibiotics     Suspected Mass     Hypercalcemia  
 NSAIDs     Anemia     Enlarged Node     B12 Deficiency  
 Chemotherapy     GI Signs     Fever     Known Disease

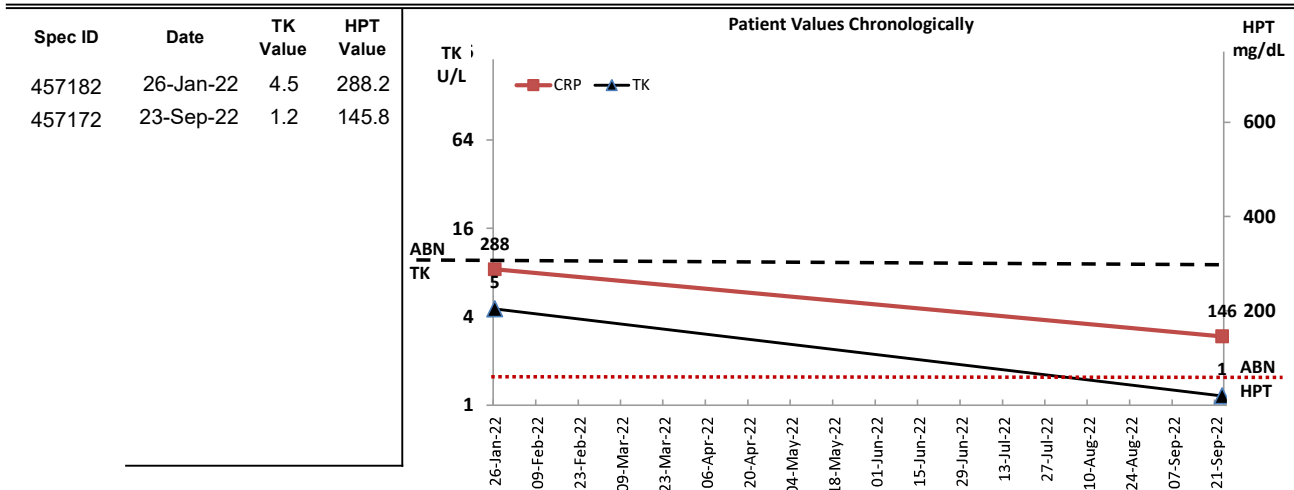
Neoplasia Index

Positive: 5.4 - 10



Interpretative Comment

Patient values for TK1 are within normal intervals however there is mild inflammation (HPT). Both TK1 and HPT showed significant improvement from prior testing. If patient is under treatment, therapy can be considered effective. If the patient is on corticosteroids, other anti-inflammatory medication, or has uncontrolled Cushing's, it can suppress HPT.



Additional Reviewer Comments - need consult? email [consult@vdlab.com](mailto:consult@vdlab.com)

Code 1222.1

All comments are general in nature and in absence of detailed knowledge of patient status or treatment.  
For case-specific consultations, please contact VDI.

Reviewer: RR