

# Feline Cancer Panel Report



**VDI Lab Services**  
 4685 Runway St. Ste K Simi Valley, CA 93063  
 ph: 805-577-6742 fax: 805-426-8115

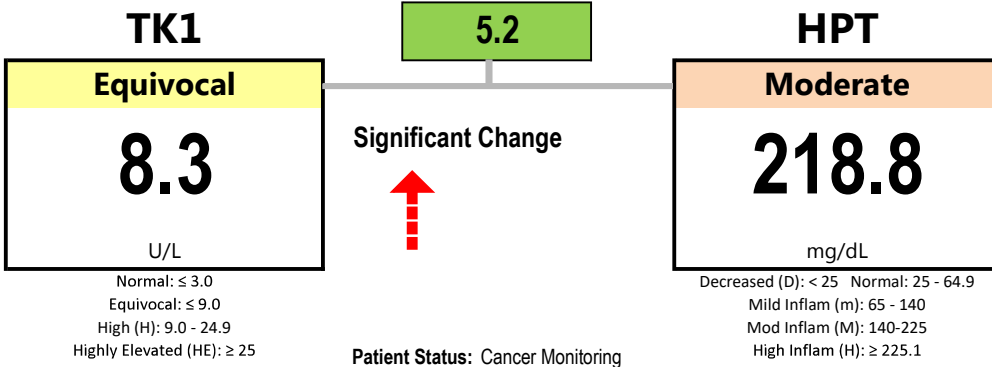
<b>PATIENT NAME:</b> Mr. Puss Hendershot	<b>MRN:</b> 1053504	<b>VETERINARIAN:</b>
<b>SPECIMEN ID:</b> 466331	<b>DRAW DATE:</b> 21-Sep-22	<b>FACILITY:</b>
<b>SPECIES:</b> Feline	<b>RECEIVED DATE:</b> 26-Sep-22	
<b>GENDER:</b> Male Neutered	<b>REPORT DATE:</b> 27-Sep-22	
<b>AGE:</b> 17.0	<b>SAMPLE TYPE:</b> Dried Serum - 2	<b>PH:</b>
<b>WEIGHT:</b> 19.9 lb	<b>PATIENT STAGE:</b>	<b>FAX:</b>
<b>BREED:</b> DSH	<b>TREATMENT:</b> unknown	

### Relevant Context (provided on TRF)

<input type="checkbox"/> >6 mo	<input type="checkbox"/> Corticosteroids	<input type="checkbox"/> Antibiotics	<input type="checkbox"/> Suspected Mass	<input type="checkbox"/> Hypercalcemia
<input type="checkbox"/>	<input type="checkbox"/> NSAIDs	<input type="checkbox"/> Anemia	<input type="checkbox"/> Enlarged Node	<input type="checkbox"/> B12 Deficiency
<input type="checkbox"/>	<input type="checkbox"/> Chemotherapy	<input type="checkbox"/> GI Signs	<input type="checkbox"/> Fever	<input type="checkbox"/> Susp. Autoimmune
				<input type="checkbox"/> Known Disease

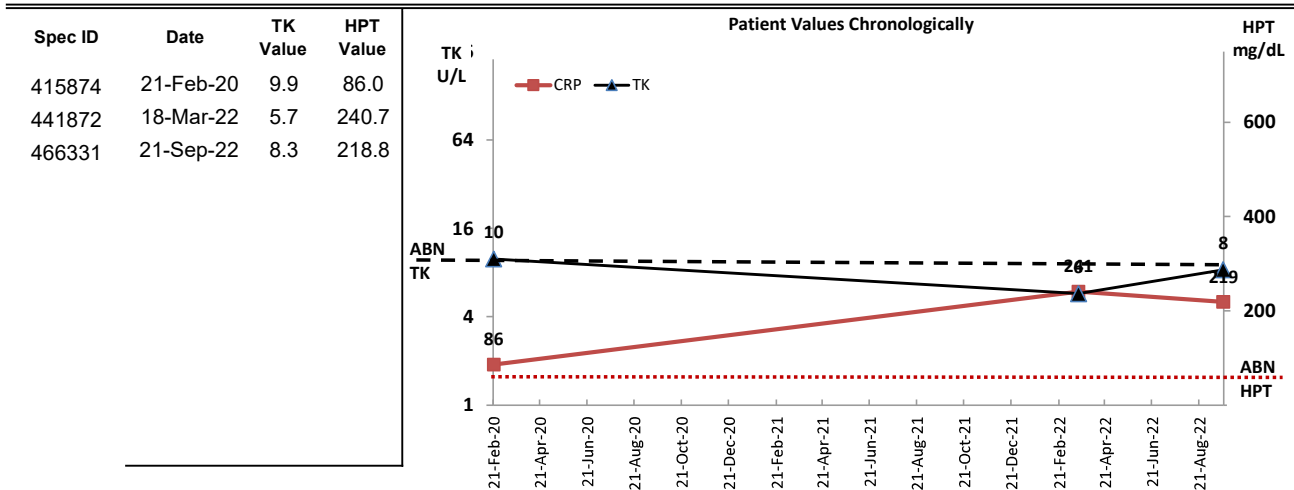
### Neoplasia Index

Positive: 5.4 - 10



### Intpretative Comment

Patient has mildly elevated TK1 with moderate inflammation (HPT). TK1 has significantly increased from prior testing. Continue monitoring for further increases in TK1. Since the patient is on corticosteroids, it may suppress HPT.



**Additional Reviewer Comments - need consult? email [consult@vdlab.com](mailto:consult@vdlab.com)**

**Code 2354.1**

All comments are general in nature and in absence of detailed knowledge of patient status or treatment.  
 For case-specific consultations, please contact VDI.

Reviewer: RR