



PATIENT NAME: Murray Wood
SPECIMEN ID: 454388
SPECIES: Feline
GENDER: Male Neutered
AGE: 14.0
WEIGHT: 10.04 lb
BREED: DSH

MRN: 1049488
DRAW DATE: 17-Mar-22
RECEIVED DATE: 23-Mar-22
REPORT DATE: 7-Oct-22
SAMPLE TYPE: Dried Serum - 2
PATIENT STAGE: Has Cancer
TREATMENT: unknown

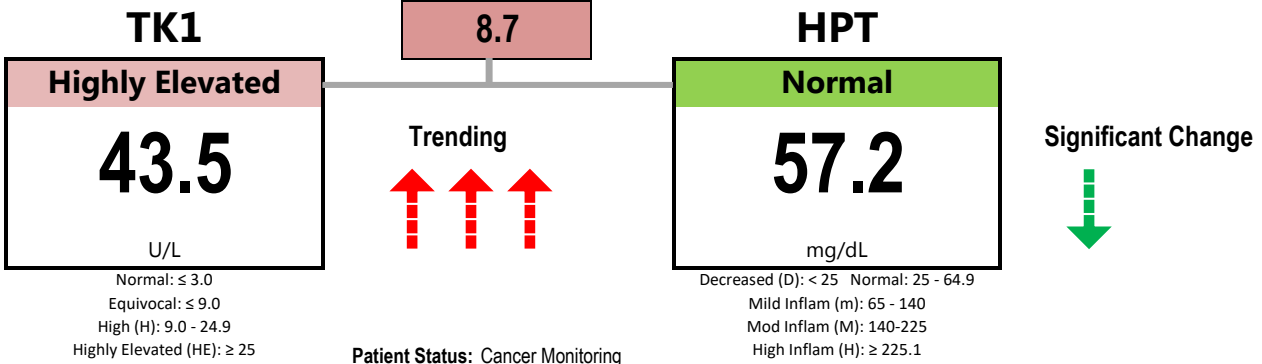
VETERINARIAN:
FACILITY:
PH:
FAX:

Relevant Context (provided on TRF)

Yes Corticosteroids Antibiotics Suspected Mass Hypercalcemia
 NSAIDs Anemia Enlarged Node B12 Deficiency
Yes Chemotherapy GI Signs Fever Known Disease

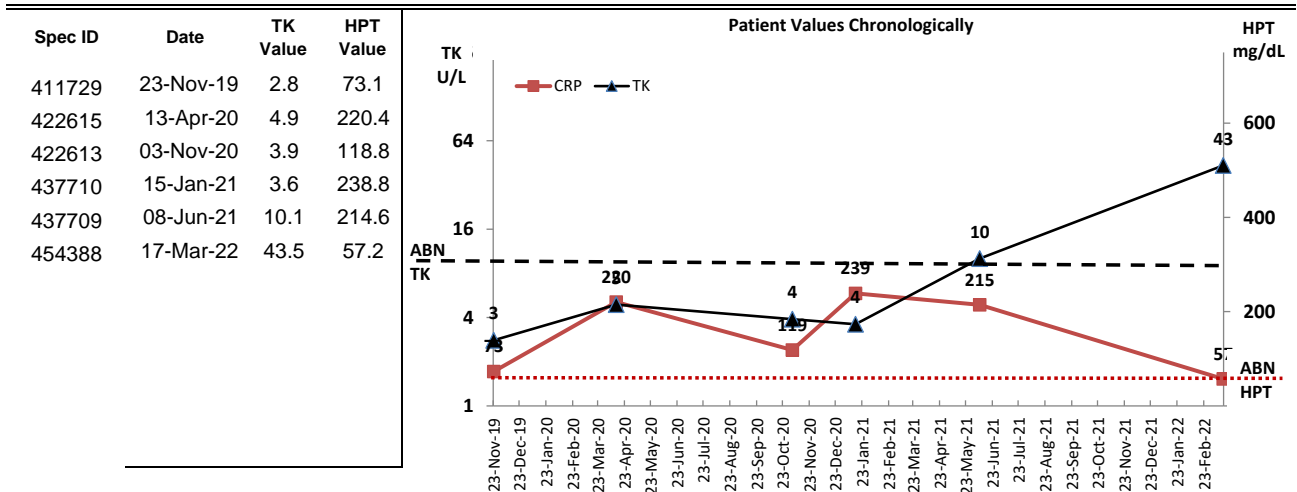
Neoplasia Index

Positive: 5.4 - 10



Intpretative Comment

Patient values for TK1 are highly elevated, but without an inflammatory response - often seen in LSA. Trending for TK1 has significantly worsen from prior testing with HPT improving. If the patient is on anti-inflammatory medications (eg, corticosteroids and NSAIDs), false suppression may be occuring and disease recurrence should be considered. Non-inflammatory increases in TK1 can occur with surgery or B12 deficiency. Recommend patient evaluation. Since the patient is on short-term corticosteroids, it may suppress both TK1 and HPT.



Additional Reviewer Comments - need consult? email consult@vdlab.com

Code 4132.3

All comments are general in nature and in absence of detailed knowledge of patient status or treatment.
For case-specific consultations, please contact VDI.

Reviewer: RR